

## **Refining Your Ability to Execute an Accurate Hruska Adduction Lift Test (HADLT)**

*Mike Cantrell MPT, PRC*

The Hruska Adduction Lift Test is a myokinematic functional assessment of a patients' ability to recruit specific muscles while simultaneously inhibiting others in opposing kinetic chains (specifically the Anterior Interior Chains [AIC]). This functional test, in conjunction with the Hruska Abduction Lift Test and the Standing Reach Test is the best myokinematic assessment of the AIC position. The comparison of left versus right allows the examiner to gain an understanding as to how obligatory one chain has become over the other. The results of the examination can then be used as a guide for the therapists' treatment plan and can aid the therapist in understanding how much progress is actually being made in treatment. Details of the exam are found in the Myokinematic Restoration course manual. These details outline the specific musculature involved with each level of the test. During some stages of the exam, the possibilities for mistakes on the part of the examiner are highlighted. Most examiner errors occur from Level "0" to level "2" of the exam. Closer scrutiny of the exam can reveal some of the reasons why examiners can incorrectly score functional performance. Deeper understanding of the biomechanics of the exam should aid in preventing assignment of erroneous scores.

### **LEVEL 0**

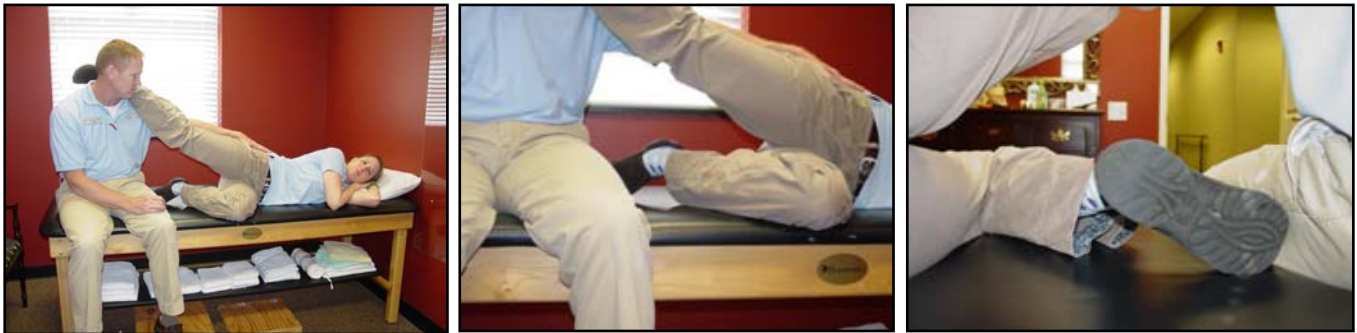As stated in the PRI Myokinematic Restoration course manual, the inability to raise the lower ankle off the mat or table is considered a "0" score. This inability reflects obturator weakness or malpositioned obturator of the flexed lower extremity. However, for a variety of reasons (outlined below) some patients cannot successfully assume the Hruska Adduction Lift Test position. A common pitfall is to allow the patient to go ahead with attempted execution of step one of the test while not being in the correct position for the test. If a patient cannot assume the test position, then that must be reflected in the exam since the exam itself is an assessment of myokinematic function. Obviously, good functional start position or mobility can be challenged in some way due to influences of the left or right AIC (the very things being examined). This level of immobility, therefore, must be understood and documented. Consequently, if a patient cannot assume the test position then the test should be halted and a score of 0 should be assigned before ever attempting to engage the obturator (Level 1 of the test).

### ***Bottom Foot Elevation***

Osseous and capsular restrictions in the femoral acetabular (FA) joint are a primary reason for some less-than-obvious incorrect positioning during the Hruska Adduction Lift Test. When these restrictions exist the examiner may witness elevation of the bottom foot off the mat as the patient attempts to position themselves in left acetabular femoral internal rotation (AF IR) (or under certain circumstances right AF IR) at the beginning of the exam.

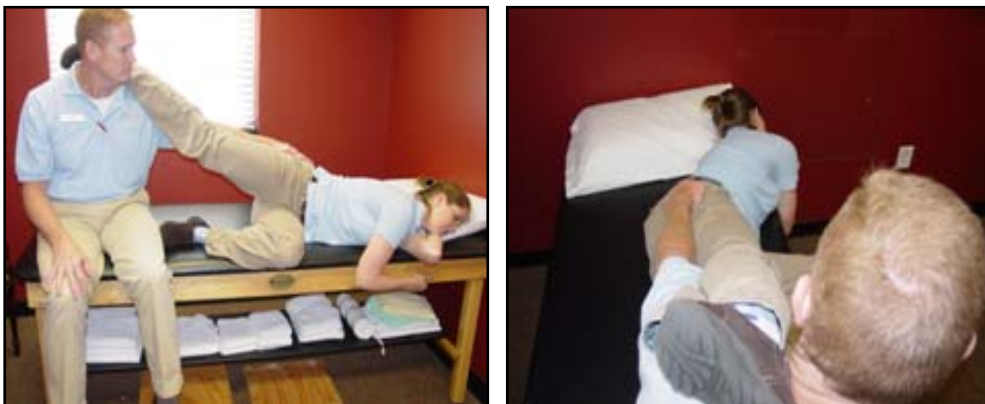Restriction of the posterior capsule or abutment of the femoral head against the posterior/inferior rim of the acetabulum, can result in "coupled" movement of the femur with the acetabulum since independent,


rotational motion of the acetabulum on the femur and the femur on the acetabulum is not present. This “coupled” movement is exhibited as elevation of the lower foot off of the mat or table. It is possible that the patient may exhibit this “coupled” motion at the FA joint due to recruitment of agonistic muscles like ipsilateral adductor magnus, piriformis and other femoral external rotators. Therefore, the examiner must carefully look for foot elevation movement and then see if the patient can lower the foot down to the table while maintaining the proper position for the test. This would indicate that the patient can inhibit those agonists and a capsular restriction may not be present. If not, then the score is a “0” before ever beginning the test.



***Excessive Trunk Rotation***

Another compensatory movement that patients may demonstrate is upper body misalignment with lower body during positioning for the Hruska Adduction Lift Test. With limitations such as a strongly patterned left AIC or Posterior Exterior Chain (PEC) the patient is likely to misalign themselves by excessively rotating the trunk as the examiner asks the patient to assume the sidelying position for the test. This maneuver is the result of limited transverse plane mobility at the FA joint (see “foot elevation” description of “coupled” motion) and efforts to overcome this limitation can result in an awkward presentation of visible excessive leftward trunk rotation (during a right HAdLT), along with possible elevation of the bottom foot off of the table. If this aberrant positioning cannot be corrected by the patient then a score of “0” must be given.





### ***Flexion of the Contralateral FA Joint***

The final common compensatory maneuver noted with limited mobility while assuming the right Hruska Adduction Lift Test position, is the tendency for the patient to align themselves with the FA joint of the extended lower extremity in a state of flexion. The instructions for the test point out that the subject should align the lower extremity, trunk and shoulder, but sometimes the patient cannot do so. Of chief concern once again, is the limitation of FA mobility on the bottom hip as described in the above paragraphs. Since the pelvis itself may be limited in ability to rotate into left AF IR the patient may flex at the FA joint of the extended lower extremity (LE) in order to feel as though they have completely shifted onto their left side and into that left FA joint.

Another reason the patient might flex at the FA joint on the extended LE is to avoid excessive lumbar extension which can occur if the patient has difficulty extending the FA joint to neutral. If the patient has difficulty extending the top lower extremity at the FA joint, the inability to shift completely into left AF IR is likely. Once again this is most commonly due to limitations in the contralateral FA joint. Rather than extending the FA joint the patient simply compensates by flexing the innominate (AF flexion) and extending the lumbar spine. The test should be halted and a score of “0” should be administered if this activity is demonstrated and cannot be corrected.

#### **LEVEL 1**

To achieve a functional score of 1, the patient has to elevate the lower ankle to the upper knee. This step in the test aids the examiner in determining if the patient has weakness of the obturator and other ER muscles of the flexed LE. It also discerns weakness of AF stabilizers of the same extremity since those AF stabilizers must be at least minimally active in order for the patient to externally rotate the femur during the test without significantly changing pelvis position or compensation from the psoas.

There are few difficulties encountered with regard to execution of this portion of the test.

#### **LEVEL 2**

At this point during the test, the client is asked to raise the lower knee off of the exam table. This portion of the test is used to determine if the patient has the ability to utilize AF and FA muscles while shifted into left AF IR. Multiple issues come into play while the patient is attempting Level 2.

### ***Pressing the Extended Extremity Too Hard Into the Examiners' Shoulder***

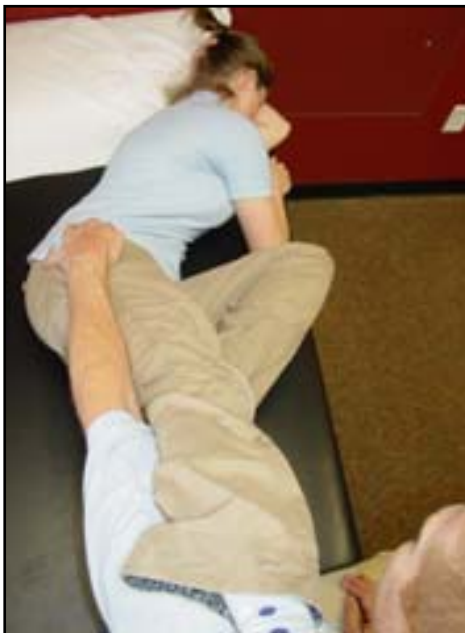The patient must be able to raise the lower knee off of the table without pressing down excessively into the examiners' shoulder with the top extremity. If the patient does indeed press down too hard with the top LE, inability to overcome ipsilateral posterior capsular tightness or osseous limitations in the FA joint during FA IR may exist. It can also indicate an inability to maintain the left AF IR position with appropriate right AIC musculature, thus recruiting agonist muscles to aid the weakness of the right AIC as well as weakness of the bottom lower extremity FA and AF muscles (anterior gluteus medius and IC

adductor). The strength of inappropriate contralateral AF muscles (adductor magnus and possibly posterior fibers of gluteus medius [top hip extension during adduction and internal rotation of the bottom femur]) also can become a factor. Erector spinae can also come into play by aiding forward (sagittal plane) rotation of the pelvis with accompanying thoracic-lumbar extension. These compensatory activities can all be detected by the examiner as excessive pressure on the examiners shoulder.

Further, if the patient is unable to maintain engagement of the ipsilateral internal obliques and transversus abdominis muscles during the Level “2” portion of the exam, attempting to internally rotate the femur will result in loss of frontal plane control of the abdominal wall. When this control is lost, the patient will bear down on the examiners’ shoulder with the contralateral lower extremity for stabilization. If the patient repeatedly presses down the top extremity into the examiners’ shoulder and correct extremity pressure or activity cannot be obtained during an attempt at Level “2” of the test, the test should be halted and a score of “1” should be administered.

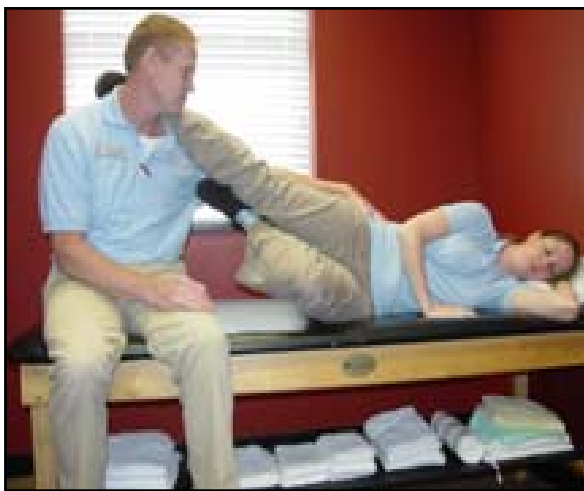### ***Flexion of Contralateral FA Joint***

The patient must be able to raise the lower knee off of the table without flexing the contralateral FA joint. Flexion of that top hip is usually the result of an inability to maintain the pelvis in a state of left AF IR while attempting left FA IR. The reason for the patients’ inability to achieve left FA IR is likely due to posterior capsular tightness of the ipsilateral FA joint or weakness of ipsilateral FA IR musculature, or weakness of contralateral AF ER musculature. When any or all of these conditions occurs the top hip rolls back giving the appearance of flexion of the top (contralateral) FA joint. If flexion occurs and cannot be corrected, the test must be halted and a score of “1” must be administered.



***Flexion of the Ipsilateral FA Joint***

The patient may appear to succeed during the attempt of achieving a Level 2 score on the right HADLT by raising the lower knee off of the exam table, but may not truly have a score of 2/5. When attempting to raise the lower knee, the patient might not actually internally rotate the left lower extremity (FA IR), but instead flexes the left LE (FA flexion). This engages the left psoas (not anterior glute medius and IC adductor) which is part of the Left AIC. Remember, the examiner is actually trying to see if the patient can *inhibit* that Left AIC during this portion of right HADLT testing. So if the left FA joint flexes, the patient is unable to inhibit the Left AIC while attempting to activate the left anterior glute medius along with the left IC adductor. A score of 1 must be given, since the patient is unable to *rotate* the left LE off of the table (left FA IR).



Normal L FA IR




Normal L FA IR



Aberrant L FA Flexion

***Inability to Isolate Appropriate Musculature on Lower Leg***

A major issue with the Level “2” portion of the right HADLT is an inability for the patient to perceive activation of appropriate muscles on the lower leg during the FA IR attempt. The muscles that should be felt working are the ipsilateral IC adductor and the gluteus medius. Both of these muscles are essential to maintain a body in a state of “left stance”. Too often the patient is unable to feel the glute med during the Level “2” attempt. The primary reason for this, is the loss of the tri-planar zone of apposition (ZOA) on the left side during the attempt. If the ZOA is lost during attempted level “2” the patient can, and usually does, feel the left IC adductor engage but the left glute medius will be more difficult to recruit. An understanding of the three planes of the ZOA helps to clarify. **Sagittal plane:** internal obliques (IO’s) and transversus abdominis (TA’s) muscles aid in sagittal plane opposition to the pelvis and lower ribs. With sagittal plane opposition, the pelvis can rotate into AF extension (necessary for true left stance). **Frontal plane:** in the frontal plane the ipsilateral IO’s and TA’s function to inhibit the contralateral IO’s and TA’s thus allowing right side elongation (necessary for left stance).



**Transverse plane:** “seating” of the lower ribs is supposed to occur during right trunk rotation, must occur during left AF IR and is essential for opposition to the diaphragm. If the patient is not truly in a state of “left stance” meaning left AF IR with tri-planar ZOA then the left gluteus medius is also not in a position of mechanical advantage for engagement and thus cannot turn the femoral head completely into the left acetabulum. Further, other agonist muscles can create a series of dyssynchronous contractions resulting in all manner of aberrant compensatory activities (see above). If the patient cannot correct this phenomenon then the test must be halted and a score of “1” must be administered.

When having the patient attempt the Level “2” portion of the HAdLT the examiner should then question the patient regarding which muscles are perceived by the patient as engaged or “working” in the lower extremity. Until the patient reports both IC adductor and glute medius working simultaneously, a score of 1/5 must be issued.

Again, the purpose for the HAdLT is to aid the examiner in understanding if the patient is ready for progression. If a patient is progressed through a PRI regimen too rapidly then failure with the rehab program will be the likely outcome. If in doubt, it is always better to grade a patient too low rather than too high on the test. Scoring too high can result in frustration on the part of the patient and the clinician as both expect greater outcomes in the following visits only to be disappointed when these outcomes are not achieved. All of this can be avoided simply by being more careful and conservative in scoring the test.

Mentioned throughout this document is that the patient should have opportunities to correct poor positioning or improper effort during the test. There is nothing wrong with helping the patient with understanding specifically what it is you require of them during the test. Indeed, this will aid you as you progress the patient through a non-manual regimen, since the patient will better understand what it is that you require of them from the test perspective. Hopefully they can then apply that understanding to the exercises prescribed.

When in doubt about position or patient ability to execute portions of the test, one may need to review the Hruska Abduction Lift Test to recognize, correct alignment for the Hruska Adduction Lift Test. This would aid in fully understanding what is required of the HAdLT. Further, the Hruska Abduction and Adduction Lift Tests are complimentary to each other and can aid you in more accurately determining true functional scores.