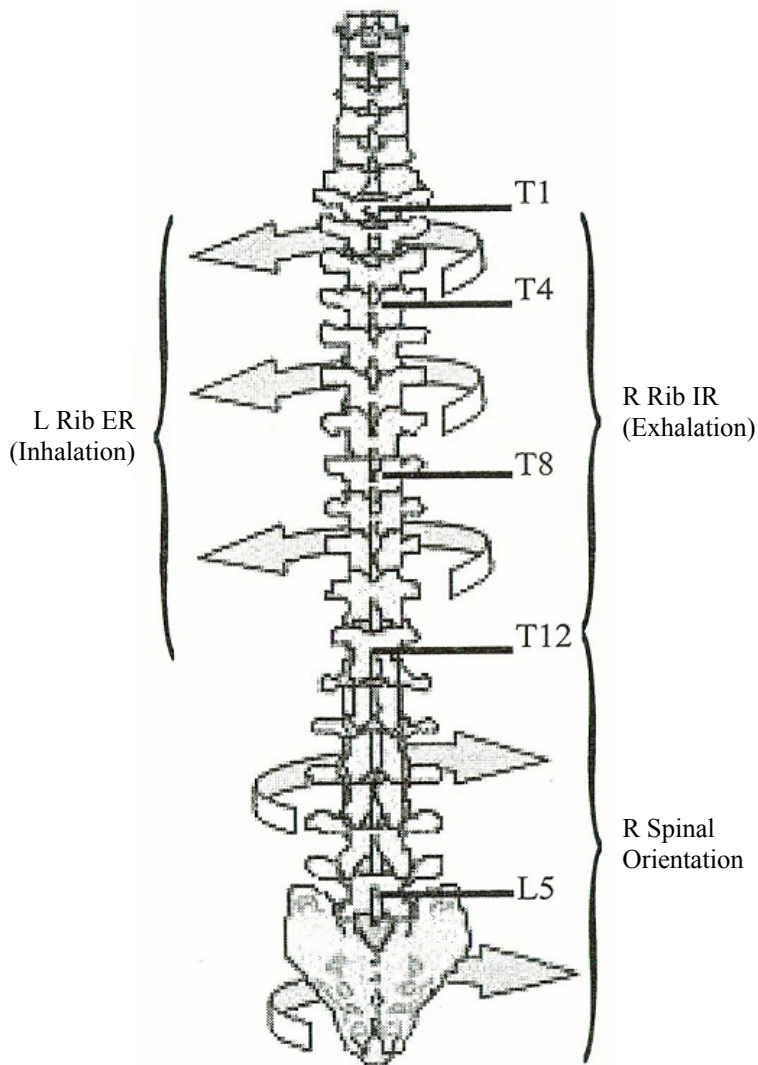


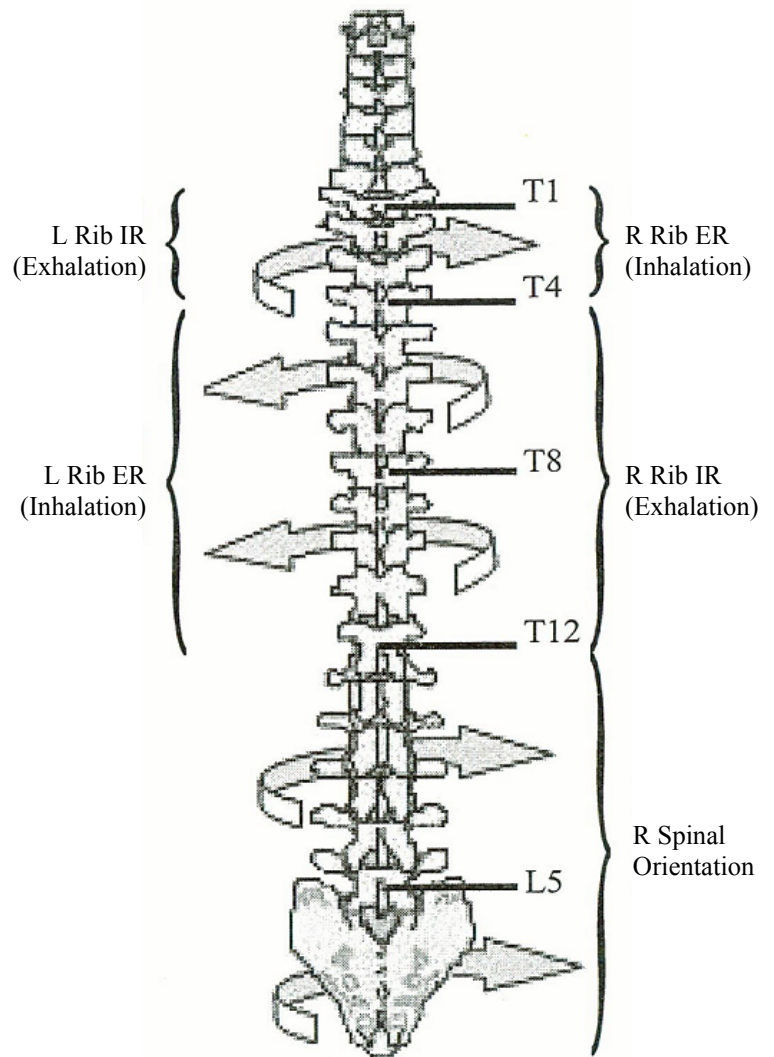
The Influence of Thoracic Airflow and Rib Rotation on Transverse Spine Position

Typical Right BC



Left AIC

Superior T4 Syndrome



Left AIC